

International Day of Radiology 2014
Interview on brain imaging
Austria / Prof. Elke Gizewski



**INTERNATIONAL
DAY OF
RADIOLOGY**
AN INITIATIVE OF THE ESR, ACR AND RSNA

This year's International Day of Radiology celebrates the development of brain imaging. The ESR spoke with Prof. Elke Gizewski, director of the department of neuroradiology at Medical University Innsbruck, Austria, about how brain imaging contributes to neurological care in Austria.

European Society of Radiology: Imaging is known for its ability to detect and diagnose diseases. What kind of brain diseases can imaging help to detect and diagnose?

Elke Gizewski: Generally, nearly all brain diseases can be detected using imaging modalities. However, some diseases have more specific characteristics in images, CT or MRI, than others. For example, one important patient group in neuroradiology: the stroke patient. Here the diagnosis is often made through clinical examination; however, to exclude cerebral bleeding and to ensure the correct therapy for the patient, only imaging can provide all information required for patient management. CT is the method of choice for excluding intracerebral bleeding. In addition, the cerebral vasculature can be easily evaluated by CT-angiography in patients with stroke.

ESR: How useful is imaging in brain disease management? Does it improve the understanding of disease or improve patient prognosis?

EG: Brain imaging is very useful in understanding brain diseases and in everyday patient management. When diagnostic catheter angiography of cerebral arteries was introduced, its time-resolved images, for example, helped us to understand steal phenomena (variable neurological symptoms) in patients with arterio-venous malformations (AVM). Today, most of our understanding of brain diseases comes from MRI studies. Patients with brain tumours, for example, can be diagnosed very precisely using multimodal MRI. This means that today not only the pathological mass in the brain can be detected, along with its extension and possible infiltration, but also the metabolism of the tumour (MR-spectroscopy) and the blood perfusion of the different tumour parts (Figure 1). These different imaging features, which can be analysed without any invasive methods, have helped us to understand tumour development. For example, the transition of a primarily low-grade tumour into a higher-grade malignant tumour, and changes related to therapy. Furthermore, imaging can help to make surgical therapies safer due to its high anatomical resolution and better preoperative assessment of tumour size and infiltration by modern imaging techniques. Functional MRI (fMRI) is very helpful for preoperative evaluation of important functional brain areas at risk. For example, in tumour patients relevant areas can be made visible before surgery to allow better planning and additional information during the surgery. Figure 2 shows an example of a brain tumour patient. The main connecting fibres are demonstrated using a special imaging sequence (DTI). Important brain areas involved in speech processing are also visualised by fMRI.

ESR: What kind of technology and techniques do radiologists use to image the brain? Are there any specific techniques for particular diseases?

EG: Conventional x-ray is still used in selected cases. However, due to the development of cross-sectional imaging techniques during the last 30 years, the diagnostic impact of conventional radiography has declined in neuroradiology. To image brain structure and possible pathologies, as well as the cerebral vessels, two modalities are best suited to the task: CT (computed tomography) and MRI (magnetic resonance imaging). For the diagnosis of vascular pathologies, DSA (digital subtraction angiography using arterial catheterisation) is essential and is also used for minimally invasive therapy in neuroradiology. Radiologists perform endovascular stroke therapy (thrombectomy) in special patients or occlusion of cerebral arterial aneurysms using endovascular coils (sometimes with additional stents or balloon). Today, most diagnoses are made using MRI,

especially if there are unclear findings in clinical presentation, laboratory tests and CT. CT is mainly used in emergency patients, brain trauma, acute stroke and initial diagnosis in other acute diseases for example. All other patients are usually transferred to MRI. As mentioned above the special MRI sequences can give additional information for differential diagnoses and important information regarding structure, metabolism and function. Besides brain tumours, all kinds of inflammation, malformations or degenerative brain pathologies are diagnosed using MRI.

ESR: What is the difference between a radiologist and a radiographer? Who else is involved in performing brain imaging exams?

EG: A radiographer is the person 'at the machine' who actually performs the x-ray, CT or MRI examinations. The confirmation of indications, mode of imaging and image interpretation is performed by the radiologist. The radiologist also communicates the diagnoses to the clinicians and discusses the findings in terms of the patient history and further examinations. In most radiological clinics physicists are also part of the team. MR systems in particular are rapidly developing and therefore technical assistance is needed for training radiologists and supporting research. Nurses are very often part of the team performing diagnostic and interventional neuroangiography. They take care of the patient during and after the procedures and often provide technical assistance comparable to assistance in a surgical theatre. Modern radiology also requires a high level of IT competence since all images are handled and processed digitally. Therefore, IT specialists are often needed for data and network care.

ESR: How many patients undergo brain imaging exams in your country each year?

EG: The statistics are available for 2012. In Austria, about 265,000 CT exams (head and neck, partly with CT angiography) were performed in 2012, about 55,200 of which were CT scans of the spine. There were about 96,200 MRI exams of the head and neck (MR angiography: 26,300; fMRI about 20,500). There were about 50,000 MRI exams of the spine. Catheter angiography of head and neck: 4,144. Coil-Embolisation of cerebral aneurysm: 358 and thrombectomy: 216.

ESR: Access to modern imaging equipment is important for brain imaging. Are hospitals in your country equipped to provide the necessary exams?

EG: Yes, in Austria the hospitals are equipped with CT and MR scanners to provide state-of-the-art neuroimaging services. Furthermore, several radiologists in private practice offer brain imaging and in some cases private institutes are equipped with CT and MR systems.

ESR: In many countries there are waiting lists for MRI exams. How long can patients typically expect to wait for an exam in Austria?

EG: This depends to a degree on each clinic. Normally, patients with urgent diseases are scanned more or less immediately. For more elective questions in clinics an average waiting time is between one and two weeks. In some institutions, especially the private ones, the waiting time is much shorter.

ESR: As the global population gets older, the risk of developing neurocognitive and neurodegenerative disorders increases. How can imaging help tackle this issue?

EG: As mentioned above, MRI is an excellent method to analyse neurocognitive and degenerative disorders. Some diseases such as Parkinson's have characteristics in brain structure which are detectable in modern MRI. Others such as cerebrovascular dementia are also easily detectable in MRI and can be followed up during therapy using this technique.

ESR: Some imaging techniques, like x-ray and CT, use ionising radiation. What risk does this radiation pose to the patient and what kind of safety measures are in place to protect the patient?

EG: As mentioned above conventional x-rays are less frequently used today and if it is used the equipment is optimised in respect of dose reduction. CT is often used in emergency and intensive care patients or other patients depending on the clinical question. In recent years, vendors have

optimised CT scanners in order to decrease radiation dose while maintaining image quality. Overall, the brain is not very sensitive to x-rays, only the eye lens has to be protected as much as possible.

ESR: What kind of role can imaging play in preventing and predicting brain diseases?

EG: This has been up to now a topic of research in many countries. Some have started multicentric enrolment of representative groups of the population for MR scanning and clinical check-up. It is presumed that for some diseases there might be an advantage of screening using imaging modalities but as neuroimaging equipment is expensive the cost versus benefit calculation has to be made.

ESR: In general, patients don't see the radiologist. A patient will discuss the image with the neurologist, neurosurgeon or oncologist. When they ask a question, they're often told "I'm not a radiologist". Why don't radiologists discuss the image with the patient first?

EG: This is a very important question: today the clinical setting in most countries does not give enough resources to the radiologists to speak with each patient. But even when it is possible, the radiologist usually sees the patient only once and has no history with the patient or the patient's clinical history. Therefore, it can be problematic for radiologists, especially regarding new or critical diagnosis, to offer patients their diagnosis. In institutes outside the clinics it is not unusual for the radiologist to discuss the imaging results with the patient.

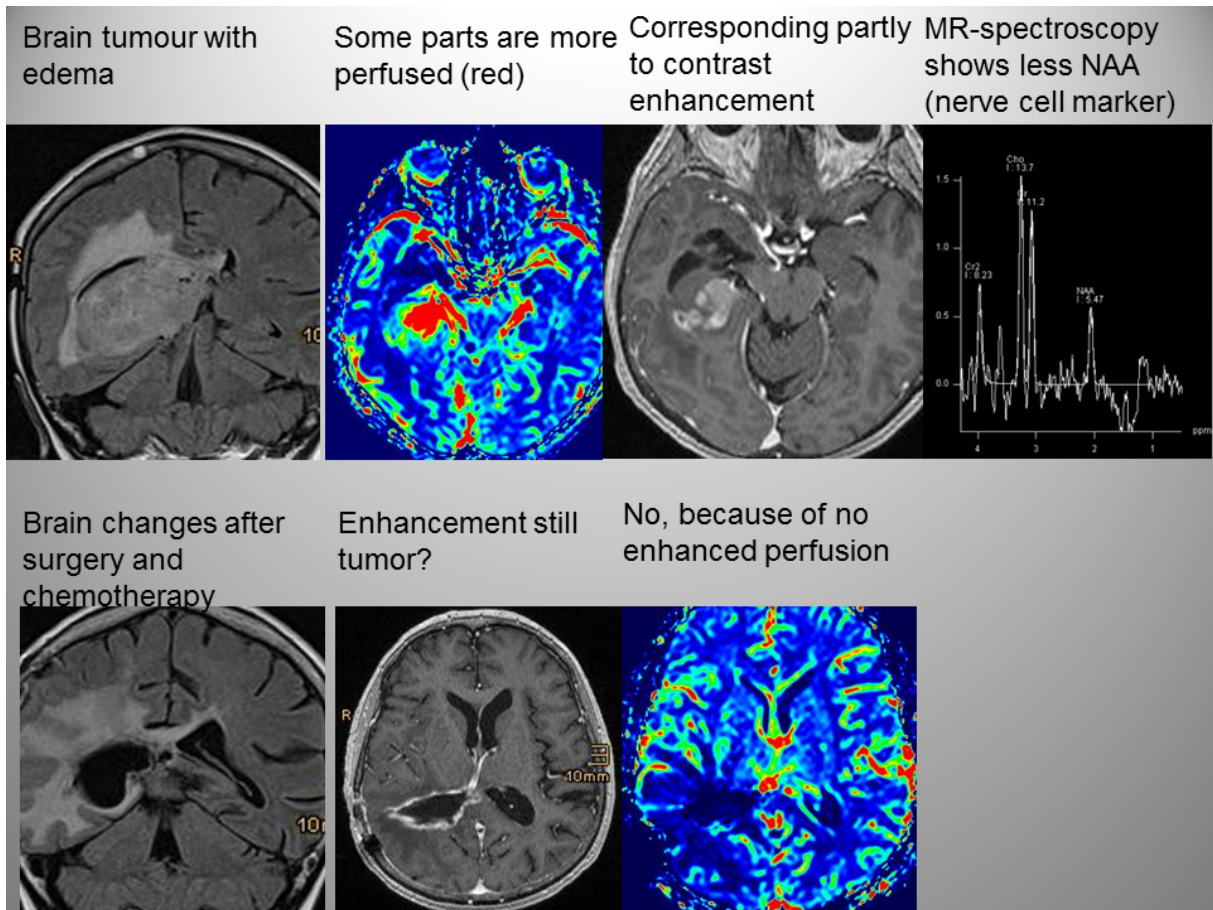
ESR: How expensive are radiological examinations to the health service and is there a risk that some of these examinations could be blocked by health technology assessment agencies deeming them to be not cost-effective? If so, how can patients help to ensure that these examinations are made available?

EG: The CT images today are not the main problem concerning high cost for the health system. However, others such as PET/CT or MRI are expensive and were in the focus of HTA analyses during the last years. The high costs of the health system and therefore also the cost intensive imaging systems are for a time in discussion and have to be a part of the politics of each country. Therefore, patients and all citizens have the opportunity to discuss the needs and priority of health openly, and, at least vote during elections. However, up to now published HTA analyses are only in some cases against the cost intensive imaging modalities. In most analyses the benefit of the imaging and the costs for further hospitalisation or other complications if diagnoses are not correctly and rapidly possible are higher than the imaging costs itself. Today, the HTA analyses are mainly focussed on the question of diagnostic benefit and accuracy.



Elke Gizewski is director of the department of neuroradiology and professor at the Medical University Innsbruck, Austria. She specialises in diagnostic neuroradiology, head & neck radiology, and interventional neuroradiology. In addition she is a board certified psychotherapist and has a master's in health business administration. She is interested in clinically driven studies dealing with diagnostic and interventional neuroradiology, and in multimodal and ultra-high field MRI with a special focus on functional MRI.

She works with many national and international groups in cerebral processing experiments of emotional and cognitive stimuli and structural brain imaging. She has authored or co-authored more than 180 original papers, 10 book chapters or monographs, and is a reviewer for more than 30 journals.



Pictures courtesy of Prof. Elke Gizewski